

Teresa Dudek-Warchoł¹, Wojciech Gług², Aleksandra Kurek², Przemysław Bombiński³,
Stanisław Warchoł¹

TESTICULAR NECROSIS SECONDARY TO INCARCERATED INGUINAL HERNIA IN MALE INFANTS. OWN OBSERVATIONS

MARTWICA JĄDRA WSKUTEK UWIĘZIENIA PRZEPUKLINY PACHWINOWEJ U NIEMOWLĄT. OBSERWACJE WŁASNE

¹Department of Pediatric Surgery and Urology, Medical University of Warsaw, Warsaw, Poland

²Student's Society for Pediatric Surgery and Urology, Medical University of Warsaw, Warsaw, Poland

³Department of Pediatric Radiology, Medical University of Warsaw, Warsaw, Poland

Abstract

One of the possible consequences of incarcerated inguinal hernia in boys is testicular ischemia because of the prolonged compression of spermatic cord structures by the sac contents, resulting in ipsilateral testicular atrophy. This complication is well described in the literature and occurs in 5-34% of patients. The incidence of testicular atrophy secondary to incarcerated hernia is estimated to be 2-3%. Testicular necrosis as the result of hernia incarceration is, however, an extremely rare clinical setting. We present 4 male infants aged 3-10 weeks with inguinal hernia incarceration which led to ipsilateral testicular loss. All the boys had to be operated on because of irreducible incarcerated hernia and in all the cases testicular necrosis was found intraoperatively. The time of incarceration before surgical intervention ranged from 4 to 12 hours (mean 6.75). Our data show that every case of hernia incarceration in a very young male infant requires rapid diagnosis and proper intervention, i.e. surgical treatment, instead of repeated attempts of manual reduction. Ultrasound examination should estimate not only blood flow through the incarcerated intestinal loop, but also through the ipsilateral testis. Moreover, during the operation of the incarcerated hernia in a boy it is necessary to estimate the ipsilateral testis.

Key words: hernia incarceration, testicular necrosis, inguinal hernia

Streszczenie

Jednym z możliwych następstw uwięzienia przepukliny pachwinowej u chłopców jest niedokrwienie jądra wskutek przedłużonego ucisku na struktury powrózka nasiennego przez zawartość worka przepuklinowego, z następowym zanikiem jądra. Powyższe powikłanie jest opisywane w piśmiennictwie i występuje u 5-34% pacjentów. Częstość występowania atrofii jądra wtórnej do uwięzienia przepukliny pachwinowej oceniana jest na 2% do 3%. Martwica jądra w wyniku uwięzienia przepukliny należy do niezmiernie rzadkich zdarzeń. W pracy przedstawiono 4 przypadki chłopców w wieku 3-10 tygodni z uwięzieniem przepukliny pachwinowej prowadzącym do martwicy jądra. Wszyscy chłopcy byli leczeni operacyjnie z powodu niedającej się odprowadzić manualnie uwięzionej przepukliny i u wszystkich śródoperacyjnie stwierdzono martwicę jądra po stronie uwięzienia. Czas trwania uwięzienia do momentu interwencji operacyjnej wynosił od 4 do 12 godzin (średni 6.75). Nasza obserwacja wskazuje na konieczność szybkiego rozpoznania i wdrożenia właściwego postępowania (leczenie operacyjne bez powtarzania kolejnych prób manualnego odprowadzenia przepukliny) w każdym przypadku uwięzienia przepukliny u chłopca w wieku wczesniemowlęcym. Ultrasonograficznie powinien być oceniany nie tylko

przepływ przez uwięzioną pętlę jelitową, ale również przez jądro po stronie uwięźnięcia oraz w czasie operacji uwięzionej przepukliny konieczna jest ocena jądra po stronie operowanej.

Słowa kluczowe: uwięźnięcie przepukliny, martwica jądra, przepuklina pachwinowa

DEV PERIOD MED. 2018;XXII,1:65-70

INTRODUCTION

Inguinal hernia in children is one of the most common congenital disorders managed by pediatricians and pediatric surgeons. Inguinal hernia repair is also one of the most common operations performed by pediatric surgeons. The main etiological factor for hernia development in children is prolonged patency of processus vaginalis, therefore indirect inguinal hernia occurs almost exclusively (in about 99% of all cases). In the general pediatric population the overall incidence of inguinal hernia is estimated at approximately 3% to 5%.

Because processus vaginalis plays an important role in testicular descent, male children with hernias outnumber females by an 8:1 to 10:1 ratio [1, 2, 3, 4].

The most serious complication of inguinal hernia is its incarceration. The risk for hernia incarceration is the highest in children less than 1 year old (70% of cases) and decreases with age. Younger age and as well as prematurity are attributed as a risk factor for incarceration [1, 2, 3, 4].

One of the possible consequences of incarcerated inguinal hernia in boys is testicular ischemia as a result of prolonged spermatic cord structure compression [1, 5, 6, 7, 8].

The aim of this study is to present a case series of male infants with testicular necrosis and its loss as a complication of incarcerated inguinal hernia.

MATERIAL AND METHODS

Over the last year 4 boys aged 3, 4, 5 and 10 weeks were diagnosed with irreducible incarcerated inguinal hernia and referred for urgent surgery. After the diagnosis of hernia incarceration at least one attempt to reduce the hernia manually was made. The clinical data of the patients are presented in Table I.

In all the boys ultrasound (US) was performed after the recognition of hernia incarceration, although in every case blood flow was checked only within the incarcerated bowel loop. The US revealed the presence of an incarcerated bowel loop within the inguinal canal. In 2 boys enlargement of the ipsilateral testis was diagnosed: in one there was slightly abnormal testicular echogenicity, in the other normal testicular structure. In the third case slight enlargement of the testis was found, with an abnormal structure, but there was visible blood flow, while in the last one the testis was described as completely normal. Only in one out of the 4 cases was there estimated blood flow through the testis (Figure 1).

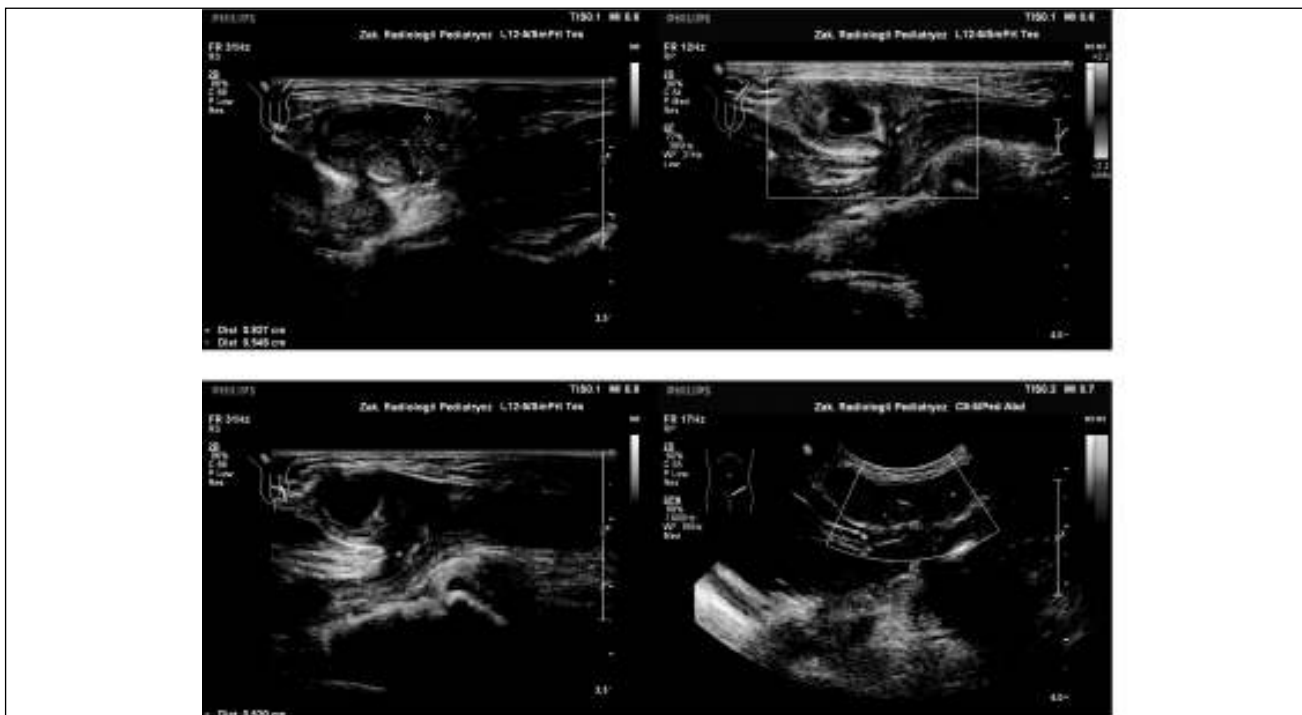


Fig. 1. US: incarcerated left inguinal hernia: intestinal loop with grossly diminished blood flow; enlarged ipsilateral testis, abnormal testicular structure, visible blood flow through the testis.

Ryc. 1. USG: uwięźnięta lewostronna przepuklina pachwinowa: pętla jelitowa ze znacznie zmniejszonym przepływem; nieznacznie powiększone lewe jądro, nieprawidłowa struktura jądra, widoczny przepływ krwi przez jądro.

Table I. Clinical data of 4 boys with testicular necrosis due to inguinal hernia incarceration.

Tabela I. Dane kliniczne 4 chłopców z martwicą jądra wskutek uwięźnięcia przepukliny pachwinowej.

Pt no Pacjent no	Age (weeks) Wiek (tygodnie)	Side Strona	Risk factors Czynniki ryzyka	US results Wynik badania USG	Time of incarceration Czas trwania uwięźnięcia
1	3	left lewa	prematurity wczesniactwo	incarcerated intestinal loop with grossly diminished blood flow <i>uwięźnięta pętla jelitowa ze znacznie zmniejszonym przepływem</i> slightly enlarged ipsilateral testis, abnormal testicular structure with visible blood flow <i>nieznacznie powiększone jądro, nieprawidłowa struktura jądra, widoczny przepływ krwi przez jądro</i>	12 hrs 12 godz.
2	4	right prawa		incarcerated intestinal loop with diminished blood flow <i>uwięźnięta pętla jelitowa ze zmniejszonym przepływem</i> enlarged ipsilateral testis, normal testicular structure, blood flow not estimated <i>powiększone jądro, prawidłowa struktura jądra, bez oceny przepływu krwi</i>	5 hrs 5 godz.
3	5	right prawa		incarcerated intestinal loop with visible blood flow <i>uwięźnięta pętla jelitowa z widocznym przepływem</i> enlarged ipsilateral testis, slightly abnormal testicular structure, blood flow not estimated <i>powiększone jądro, nieco nieprawidłowa struktura jądra, bez oceny przepływu krwi</i>	6 hrs 6 godz.
4	10	left lewa	prematurity wczesniactwo	incarcerated intestinal loop with visible blood flow <i>uwięźnięta pętla jelitowa z widocznym przepływem</i> normal ipsilateral testis, blood flow not estimated <i>prawidłowe jądro, bez oceny przepływu krwi</i>	4 hrs 4 godz.

RESULTS

Table II presents the details of operative findings, as well as details of applied surgical management. Intraoperatively testicular necrosis with no torsion of spermatic cord structures was found in all 4 boys, despite an incarcerated bowel loop (Figure 2). In 3 the incarcerated intestinal loop estimated as viable was reduced, in the remaining 4th patient bowel resection with primary anastomosis was necessary, because of concomitant bowel necrosis. As the attempts of revascularization of the testes by their warming and local lidocaine injection were ineffective (Figure 3), orchiectomy was performed in all the patients. The postoperative course was uneventful and the patients were discharged home 3 to 6 days after surgery.

The histopathological examination of the removed testes showed hemorrhagic infarction with necrosis in all the cases.

DISCUSSION

The vascular supply to the testis may be compromised by the incarcerated bowel, resulting in ischemia of the ipsilateral testis. The possibility of such testicular injury during inguinal hernia incarceration is a known clinical entity with reported occurrence of testicular ischemia from 5 to 34% [1, 5, 6, 7, 8, 9]. Prolonged testicular ischemia can finally result in testicular atrophy. The reported incidence of this complication is 2 to 3% [1, 2, 5, 6, 7, 8].

Table II. Operative findings and details of applied surgical management.

Tabela II. Dane śródoperacyjne oraz sposób postępowania.

Pt no Pacjent no	Time of incarceration Czas trwania uwięźnięcia	Intraoperative findings Dane śródoperacyjne	Intervention Postępowanie
1	12 hrs 12 godz.	necrotic incarcerated intestinal loop <i>martwiczo zmieniona uwięźnięta pętla jelitowa</i> necrotic ipsilateral testis (no torsion of spermatic cord structures) <i>martwiczo zmienione jądro (bez skrętu elementów powrózka)</i>	intestinal resection/anastomosis <i>resekcja/zespolecie jelita orchiectomy usunięcie jądra</i>
2	5 hrs 5 godz.	viable incarcerated intestinal loop <i>przekrwiona, obrzęknięta uwięźnięta pętla jelitowa</i> necrotic ipsilateral testis (no torsion of spermatic cord structures) <i>martwiczo zmienione jądro (bez skrętu elementów powrózka)</i>	hernia reduction <i>odprowadzenie pętli jelitowej orchiectomy usunięcie jądra</i>
3	6 hrs 6 godz.	viable incarcerated intestinal loop <i>przekrwiona, obrzęknięta uwięźnięta pętla jelitowa</i> necrotic ipsilateral testis (no torsion of spermatic cord structures) <i>martwiczo zmienione jądro (bez skrętu elementów powrózka)</i>	hernia reduction <i>odprowadzenie pętli jelitowej orchiectomy usunięcie jądra</i>
4	4 hrs 4 godz.	viable incarcerated intestinal loop <i>przekrwiona, obrzęknięta uwięźnięta pętla jelitowa</i> necrotic ipsilateral testis (no torsion of spermatic cord structures) <i>martwiczo zmienione jądro (bez skrętu elementów powrózka)</i>	hernia reduction <i>odprowadzenie pętli jelitowej orchiectomy usunięcie jądra</i>

Within an incarcerated hernia which undergoes operative treatment, the testis of the affected side is usually found to be edematous and also somewhat cyanotic. Generally, unless the gonad is frankly necrotic, it is postulated to preserve the testis. In such cases the parents of each boy should be informed about the possibility of testicular diminishing and atrophy in the future [1, 2, 5, 6].

A very limited number of reports regarding testicular infarction/necrosis/gangrene caused by an incarcerated inguinal hernia are available in the literature and almost all of them are case reports. So far one can find 16 reports in Pub Med [5-8, 10-22].

In most of the published reports it is stated that testicular injury was not anticipated but was incidentally found during the operation. All the cases described referred to boys who required emergency operations because of an irreducible hernia. Moreover, testicular injury was typically noted in very young male infants, usually less than 3 months of age. All of our patients were also within

the first 3 months of their lives (the oldest one was 10 weeks) and all were referred for urgent surgery because of irreducible incarcerated inguinal hernias.

To date we have not found a similar case series presented in the literature. We were able to find only two similar single cases, including one with necrosis of an undescended testis by an incarcerated hernia [21, 22].

CONCLUSIONS

Our observations confirm that the reduction of the incarcerated inguinal hernia should be performed as early as possible, not only to preserve the bowel, but also to avoid excess pressure on the spermatic cord structures with possible testicular injury. On the other hand it seems that incarceration in a very young male infant requires proper intervention, i.e. operative treatment instead of repeated attempts of manual reduction, so as to avoid additional injury to the testis. It is also worth emphasizing

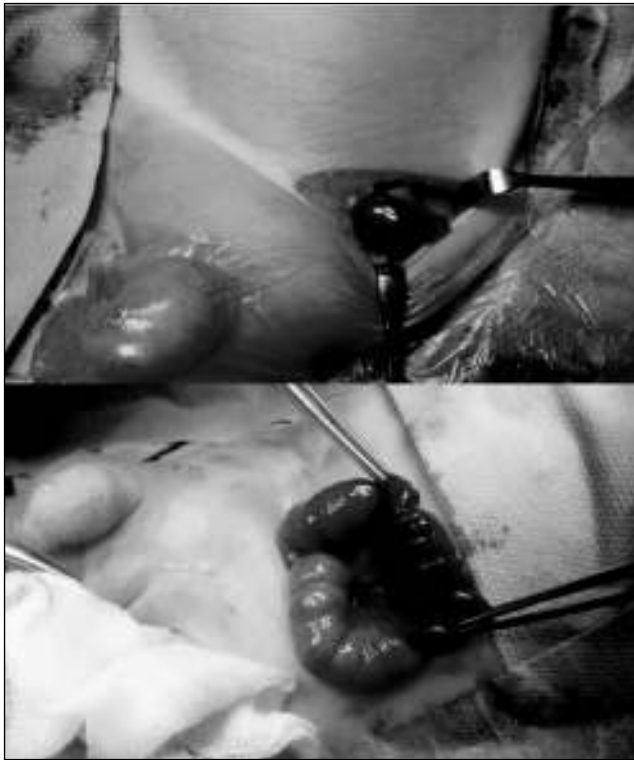

Fig. 2. Intraoperative view: incarcerated left inguinal hernia: necrosis of the testis.

Ryc. 2. Zdjęcie śródoperacyjne: uwięźnięta lewostronna przepuklina pachwinowa: martwiczo zmienione jądro.

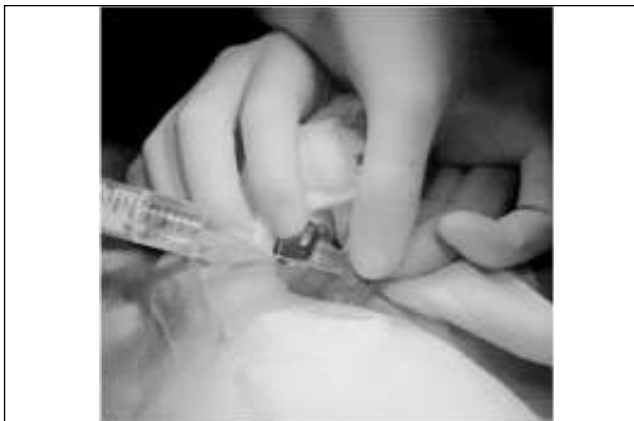

Fig. 3. Intraoperative view: local lidocaine injection.

Ryc. 3. Zdjęcie śródoperacyjne: miejscowe ostrzyknięcie lignokainą.

that the initial ultrasound examination should estimate not only blood flow through the incarcerated inguinal loop, but also through the ipsilateral testis. During the operation of an incarcerated hernia in a boy it is necessary to estimate the ipsilateral testis.

REFERENCES

1. Snyder ChL. Inguinal hernias and hydroceles. Ashcraft's Pediatric Surgery. Saunders Elsevier. Philadelphia. 2010.

2. Lau ST, Yi-Horng L, Caty MG. Current management of hernias and hydroceles. *Sem Pediatr Surg.* 2007;16:50-57.

3. Esposito C, Escolino M, Turra F, Roberti A, Cerulo M, Farina A, Caiazza S, Cortese G, Servillo G, Settimi A. Current concepts in the management of inguinal hernia and hydrocele in pediatric patients in laparoscopic era. *Sem Pediatr Surg.* 2016;25:50-57.

4. Ein SH, Njere I, Ein A. Six thousand three hundred sixty-one pediatric inguinal hernias: a 35-year review. *J Pediatr Surg.* 2006;41:980-986.

5. Puri P, Guiney EJ, O'Donnell B. Inguinal hernia in infants: the fate of the testis following incarceration. *J Pediatr Surg.* 1984;19(1):44-46.

6. Alyami F, Whelan T. Incarcerated inguinal hernia in infancy associated with testicular infarction: case report and review of the literature. *Can Urol Assoc J.* 2013;7(5-6): E367-E369.

7. Orth RC, Towbin AJ. Acute testicular ischemia caused by incarcerated inguinal hernia. *Pediatr Radiol.* 2012;42:196-200.

8. Ozdamar MY, Karakus OZ. Testicular ischemia caused by incarcerated inguinal hernia in infants: incidence, conservative treatment procedure, and follow-up. *Urol J.* 2017;14(4):4030-4033.

9. Niedzielski J, Król R, Gawłowska A. Could incarceration of inguinal hernia in children be prevented? *Med Sci Monit.* 2003;9(1):CR16-18.

10. Waseem M, Pinkert H, Devas G. Testicular infarction becoming apparent after hernia reduction. *J Emerg Med.* 2010;38(40):460-462.

11. Schmitt M, Peiffert B, de Miscault G, Bartheleme H, Poussot D, Andre M. [Complications of inguinal hernia in children] [article in French]. *Chir Pediatr.* 1987; 28(4-5):193-196.

12. Le Coultre C, Cuendet A, Richon J. Frequency of testicular atrophy following incarcerated hernia. *Z Kinderchir.* 1983 Apr; 38 Suppl:39-41.

13. Hager J, Menardi G. [Ischemic damage of the testis as a complication of incarcerated hernia in the infant] [article in German]. *Padiatr Padol.* 1986;21(1):17-24.

14. Gamble WG, Keller GA. Testicular infarction associated with incarcerated inguinal hernia. *Minn Med.* 1987;70(9):529-532.

15. McGurk MN. Testicular infarction with incarcerated inguinal hernia in infants. *N Z Med J.* 1987;88(615):14.

16. Laube J, Bellmann J. [Irreversible infarction of testis and ovary due to incarcerated inguinal hernia in the newborn] [article in German]. *Zentralbl Chir.* 1977;102(12):744-748.e

17. Hanna BK. Incarcerated inguinal hernia in infancy associated with testicular infarction. *J Ir Med Assoc.* 1972;65(14):372-373.

18. Rao VB, Dhawan IK. Testicular gangrene due to an incarcerated inguinal hernia in an infant. *J Indian Med Assoc.* 1965;45(11):618.

19. Deshpande PV. Testicular gangrene in infancy due to incarcerated inguinal hernia. *Br J Surg.* 1964 Mar;51:237-238.

20. Hill MR jr, Pollock WF, Sprong DH jr. Testicular infarction and incarcerated inguinal herniae. *Arch Surg.* 1962 Aug;85:351-354.

21. Romero Perez P, Amant Cecilia M, Santos Serrano L, Llobat Estelles T, Benlloch Muncharaz MJ, Patricio Talayero JM, Aranda Lopez I, Lobato Encinas JJ. [Necrosis of undescended testis caused by incarcerated inguino-scrotal hernia in a newborn]. [article in Spanish] *Actas Urol Esp.* 1995;19(2):159-165.
22. Galbarriatu Gutierrez A, Blanco Bruned JL, Solaexte PN, Oliver Linares F. [Testicular loss secondary to incarcerated inguinal hernia in the infant]. [article in Spanish] *An Pediatr (Barc).* 2013;79(1):58-60.

Author's contributions/Wkład Autorów

According to the order of the Authorship/Według kolejności

Conflicts of interest/Konflikt interesu

The Authors declare no conflict of interest.

Autorzy pracy nie zgłaszają konfliktu interesów.

Received/Nadesłano: 08.11.2017 r.

Accepted/Zaaceptowano: 06.12.2017 r.

Published online/Dostępne online

Address for correspondence:

Teresa Dudek-Warchoł

Department of Pediatric Surgery and Urology,

Medical University of Warsaw,

02-091 Warsaw, Żwirki & Wigury street 63a, Poland

e-mail: swarchol@poczta.onet.pl